Indian Journal of Surgical Oncology (September 2020) 11 (Suppl 1):S48–S51
https://doi.org/10.1007/s13193-019-01027-z

CASE REPORT

Calcaneal Reconstruction by Proximal Tibia Allograft Following Total Calcanectomy

Suraj Hindiskere[1] · Saurodeep Bhattacharjee[1] · Srinath Doddarangappa[1] · Pramod S. Chinder[1]

Received: 25 May 2019 / Accepted: 12 December 2019 / Published online: 26 December 2019

Introduction

Primary malignant bone tumour of the calcaneum is rare and constitutes about 3% of all bone tumours [1]. Due to its rarity, delayed diagnosis and inadequate treatment, local recurrence is common; literature with regard to the available surgical options and outcome is also limited [2,3].

Osteosarcoma, chondrosarcoma and Ewing's sarcoma are the common malignant tumours of the calcaneum [4]. Malignant tumours of the calcaneum tend to perforate the cortex early in their course, becoming extra compartmental [5]. Below-knee amputation was previously considered the standard treatment, but with the advent of chemotherapy, advanced imaging and surgical techniques, limb salvage has become the treatment of choice for primary calcaneal malignancy [6,3].

Since majority of the tumour vicinity is free from important neurovascular structures, total calcanectomy is a viable option for malignant tumours of the calcaneum [7]. Different reconstructive methods like allograft, recycled autograft, prosthesis and vascularized osseous flaps have been described, with their respective advantages and disadvantages [8–11]. We report a novel technique of using a fresh-frozen proximal tibia allograft, for structural reconstruction of the hindfoot, following total calcanectomy.

Case Report

A 29-year-old male was evaluated clinic-radiologically for pain and swelling over the outer aspect of the right heel. An incisional biopsy was performed elsewhere for an osteolytic, expansile lesion in the body of the right calcaneum and was referred to us as the biopsy was suggestive of a grade II chondrosarcoma.

On radiological re-evaluation, a FDG avid permeative, destructive osseous lesion with stippled chondroid calcification, involving the body of the right calcaneum measuring approximately 4.8 × 5.3 cm (cm) with SUV of 10.3, was evident on PET-CT scan (Fig. 1). The lateral cortex was breached with signs of soft tissue extension. On MRI scan, the lesion was isointense on T1 and hyperintense on T2 imaging, with no signs of articular extension. Considering the extent of the lesion, he was planned for total calcaneal resection and reconstruction (Fig. 2).

Under general anaesthesia and following preoperative antibiotic prophylaxis, patient was placed in left lateral decubitus position on the operating table. Curvilinear incision including the incisional biopsy scar was chosen over the lateral aspect of the right hindfoot. The subcutaneous tissue was dissected and separated from the underlying soft tissue tumour extension, maintaining adequate margin. Superior and inferior peroneal retinaculum were released; peroneus longus and peroneus brevis tendons were retracted superiorly without releasing it from its attachment. Complete calcaneum, talocalcaneal and calcaneocuboid joints were exposed after confirming that the tumour had not entered the articular surface. Tendoachillis was cut about 1 cm from its attachment on the calcaneum, and the ligamentous attachments were released off the calcaneum (Fig. 3). Total calcanectomy was completed after disarticulating the subtalar and midtarsal joints, and the calcaneum was removed without any contamination of the tumour bed. Thorough wash was given with pulsed saline lavage and haemostasis achieved.

Fresh-frozen proximal tibia allograft was obtained from a certified bone bank and thawed in room temperature for 30 min. Sterile package was opened, and the allograft was washed with multiple cycles of normal saline and finally with 80 mg (2 ml) of gentamicin. The articular cartilage of the tibial condyles of the allograft was denuded; struts of fibular

✉ Suraj Hindiskere
suraj.ortho@gmail.com

[1] Department of Musculoskeletal Oncology, HealthCare Global Enterprises Ltd (HCG) Hospital, No. 8, P. Kalinga Rao Road, Sampangiramnagar, Bangalore 560020, India

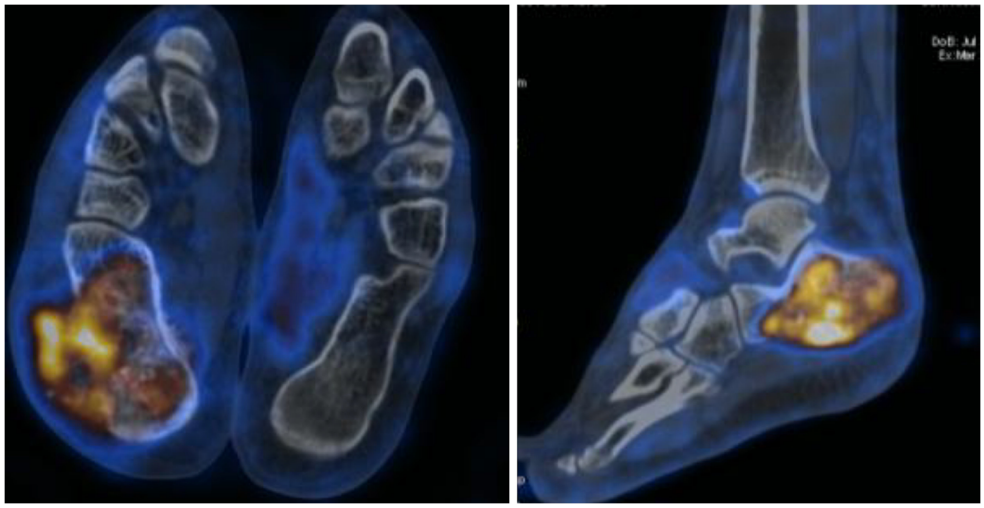

Fig. 1 PET-CT scan image with an osteolytic FDG avid lesion in the right calcaneum with lateral cortical breach and soft tissue extension

allografts were packed into the medullary canal of the tibia allograft. The allograft construct was implanted into the hindfoot, with the proximal wide condylar aspect of the tibia allograft facing posteriorly and secured with anchoring K-wires. Tendoachillis was sutured to the allograft, which was further secured to the talus and cuboid at the respective articular surfaces using multiple cancellous screws and Herbert screw (Fig. 4). The position of the graft and screws was confirmed under by intraoperative radiograph, and primary closure was achieved over a suction drain. Compression dressing was applied; the operated limb was stabilized with an above knee plaster slab with ankle in neutral position and knee in 30degrees of flexion.

Postoperatively, intravenous antibiotics were administered for 5 days. Wound drain was removed on the fourth postoperative day, and the dressing was changed every fourth day till the sutures were removed on the seventeenth postoperative day. The above knee plaster slab was changed to a below knee plaster cast after suture removal, which was maintained for 3 months after surgery and then changed to an Aircast. Patient was started on non-weight bearing ambulation on the first post-operative day. Partial weight bearing (20%) was started after 3 months of surgery and was gradually increased by 20% every 6 weeks, with crutch support and Aircast.

During follow-up, patient was full weight bearing and ambulating without support by 8 months after surgery. At final follow-up of 36 months, MSTS score was 29 with no signs of local recurrence or distant metastasis (Fig. 5). The dorsiflexion and the plantar flexion at the ankle joint were 20° and 40°, respectively; and the subtalar joint had 15° inversion and 5° eversion.

Fig. 2 Clinical preoperative image of the right heel

Discussion

Primary malignant bone tumour of the foot is very rare, and calcaneum is the most common bone of the foot to be involved [4]. Due to poor soft tissue envelope and complex relations of tarsal bones with one another, obtaining wide margin resection for malignant tumour is challenging, and inadequate treatment leads to local recurrence and subsequent poorer survival rates

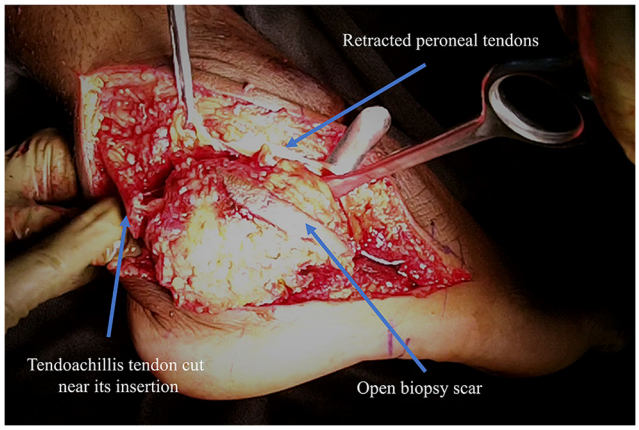

Fig. 3 Clinical intraoperative image, with dissected calcaneum prior to total calcanectomy

Fig. 4 Follow-up lateral view plain radiograph of operated site with proximal tibial allograft

[12]. Below-knee amputation for malignant tumour of the foot has been recommended for many years since it provided good functional outcome [13]. Limb salvage by time-consuming complex surgical techniques is now preferred in view of better functional status and psychological acceptance, compared to patients with amputation [14,15].

Calcanectomy without reconstruction provides satisfactory function; however, cosmetic deformity, ulceration of the skin and additional deformities frequently occur [16,17]. The goals of reconstructing the hindfoot after partial or total calcanectomy are to maintain the height of the hindfoot to preserve normal tarsal biomechanics and to restore adequate soft tissue coverage [5]. The calcaneum forms the posterior aspect of the tripod of a 3-point gait, which is an essential part of physiological locomotion. Following resection, the volume of calcaneum to be replaced should be similar to the amount resected, and graft with larger volume is better than fibula or rib grafts [11].

Custom-made 3D-printed prosthesis and vascularized pelvic bone or fibular autografts are options for calcaneal reconstructions [8,18,19,11,5]. Fresh-frozen calcaneal allograft reconstruction following partial or total calcanectomy has been used for many years, and favourable functional and oncological outcome have been reported in the literature [20,21,9]. Ayerza et al. reported allograft survival of 79% at 5 and 10 years following structural reconstruction for foot and ankle tumour resections [22]. In their series, six patients underwent calcaneal resection and reconstruction by either total calcaneal allografts (five) or partial calcaneal allograft (one), with an allograft survival of 83%. But there are very few reports regarding the use of other allografts for calcaneum reconstruction [23,9,24,20,5]. Similar to our report, Wozniak et al. used fresh-frozen femoral head and neck for calcaneal reconstruction in children and reported good functional outcome [24].

Fig. 5 Clinical picture of operated site at final follow-up

According to the combined knowledge of the authors, there is no report in the literature of a fresh-frozen proximal tibia allograft for calcaneal reconstruction, following total calcanectomy for a primary malignant tumour; and this is the first report of such reconstruction. The authors feel that for reconstruction of calcaneum following resection for tumour or any other cause, maintaining the volume of the hindfoot is important to achieve good long-term functional outcome. In institutes or countries where fresh-frozen size or site-matched allografts are not available, nonanatomical allografts can be used if it matches the morphology. Longer follow-up is warranted as large fresh-frozen allografts can undergo resorption leading to collapse [9].

References

1. Kilgore WB, Parrish WM (2005) Calcaneal tumors and tumor-like conditions. Foot Ankle Clin 10(3):541–565, **vii**. https://doi.org/10.1016/j.fcl.2005.05.002
2. Biscaglia R, Gasbarrini A, Bohling T, Bacchini P, Bertoni F, Picci P (1998) Osteosarcoma of the bones of the foot–an easily misdiagnosed malignant tumor. Mayo Clin Proc 73(9):842–847. https://doi.org/10.4065/73.9.842
3. Li J, Wang Z (2014) Surgical treatment of malignant tumors of the calcaneus. J Am Podiatr Med Assoc 104(1):71–76. https://doi.org/10.7547/0003-0538-104.1.71
4. Casadei R, Ferraro A, Ferruzzi A, Biagini R, Ruggieri P (1991) Bone tumors of the foot: epidemiology and diagnosis. La Chirurgia degli organi di movimento 76(1):47–62
5. Li J, Wang Z, Guo Z, Yang M, Chen G, Pei G (2012) Composite biological reconstruction following total calcanectomy of primary calcaneal tumors. J Surg Oncol 105(7):673–678. https://doi.org/10.1002/jso.23022
6. Choong PF, Qureshi AA, Sim FH, Unni KK (1999) Osteosarcoma of the foot: a review of 52 patients at the Mayo Clinic. Acta Orthop Scand 70(4):361–364
7. Li J, Wang Z (2014) Surgical treatment of malignant tumors of the calcaneus. J Am Podiatr Med Assoc 104(1):71–76
8. Chou LB, Malawer MM (2007) Osteosarcoma of the calcaneus treated with prosthetic replacement with twelve years of followup: a case report. Foot & ankle international 28(7):841–844. https://doi.org/10.3113/fai.2006.0841
9. Muscolo DL, Ayerza MA, Aponte-Tinao LA (2000) Long-term results of allograft replacement after total calcanectomy. A report of two cases. J Bone Joint Surg Am 82(1):109–112
10. Scoccianti G, Campanacci DA, Innocenti M, Beltrami G, Capanna R (2009) Total calcanectomy and reconstruction with vascularized iliac bone graft for osteoblastoma: a report of two cases. Foot & ankle international 30(7):716–720. https://doi.org/10.3113/fai.2009.0716
11. Kurvin LA, Volkering C, Kessler SB (2008) Calcaneus replacement after total calcanectomy via vascularized pelvis bone. Foot and ankle surgery : official journal of the European Society of Foot

and Ankle Surgeons 14(4):221–224. https://doi.org/10.1016/j.fas.2008.03.004
12. Brotzmann M, Hefti F, Baumhoer D, Krieg AH (2013) Do malignant bone tumors of the foot have a different biological behavior than sarcomas at other skeletal sites? Sarcoma 2013:767960–767960. https://doi.org/10.1155/2013/767960
13. Mascard E, Gaspar N, Brugières L, Glorion C, Pannier S, Gomez-Brouchet A (2017) Malignant tumours of the foot and ankle. EFORT open reviews 2(5):261–271. https://doi.org/10.1302/2058-5241.2.160078
14. Papagelopoulos PJ, Mavrogenis AF, Badekas A, Sim FH (2003) Foot malignancies: a multidisciplinary approach. Foot Ankle Clin 8(4):751–763. https://doi.org/10.1016/S1083-7515(03)00150-5
15. AL H, BHC F, JN L, Fs G, A C, HG S, HK S (2008) Limb-sparing surgery preserves more function than amputation. The Journal of Bone and Joint Surgery British volume 90-B(6):786–794. https://doi.org/10.1302/0301-620x.90b6.19805
16. Dhillon MS, Singh B, Gill SS, Walker R, Nagi ON (1993) Management of giant cell tumor of the tarsal bones: a report of nine cases and a review of the literature. Foot & ankle 14(5):265–272. https://doi.org/10.1177/107110079301400506
17. Smith DG, Stuck RM, Ketner L, Sage RM, Pinzur MS (1992) Partial calcanectomy for the treatment of large ulcerations of the heel and calcaneal osteomyelitis. An amputation of the back of the foot. J Bone Joint Surg Am 74(4):571–576. https://doi.org/10.2106/00004623-199274040-00013
18. Imanishi J, Choong PFM (2015) Three-dimensional printed calcaneal prosthesis following total calcanectomy. Int J Surg Case Rep 10:83–87. https://doi.org/10.1016/j.ijscr.2015.02.037
19. Innocenti M, Lucattelli E, Daolio PA, Bastoni S, Marini E, Scoccianti G, Menichini G (2019) Calcaneal reconstruction after total calcanectomy with iliac crest free flap. Microsurgery. https://doi.org/10.1002/micr.30452
20. Aponte-Tinao LA, Ritacco LE, Albergo JI, Ayerza MA, Muscolo DL, Farfalli GL (2014) The principles and applications of fresh frozen allografts to bone and joint reconstruction. Orthop Clin N Am 45(2):257–269. https://doi.org/10.1016/j.ocl.2013.12.008
21. Mankin HJ, Gebhardt MC, Jennings LC, Springfield DS, Tomford WW (1996) Long-term results of allograft replacement in the management of bone tumors. Clin Orthop Relat Res 324:86–97. https://doi.org/10.1097/00003086-199603000-00011
22. Ayerza MA, Piuzzi NS, Aponte-Tinao LA, Farfalli GL, Muscolo DL (2016) Structural allograft reconstruction of the foot and ankle after tumor resections. Musculoskelet Surg 100(2):149–156. https://doi.org/10.1007/s12306-016-0413-4
23. Degeorge B, Dagneaux L, Forget D, Gaillard F, Canovas F, #xe7, ois (2016) Delayed reconstruction by total calcaneal allograft following calcanectomy: is it an option? Case Reports in Orthopedics 2016:5. doi:https://doi.org/10.1155/2016/4012180
24. Woźniak W, Raciborska A, Walenta T, Szafrański A, Szymborska A, Bajor M (2007) New technique of surgical treatment of malignant calcaneal tumours. Preliminary report. Ortop Traumatol Rehabil 9(3):273–276