

# Recurrent Giant Cell Tumor of Sacrum Treated with Denosumab: A Case Report

Pramod Chinder<sup>1</sup>, Suresh Rao<sup>2</sup>, Naveen Joseph Mathai<sup>3</sup>, Manjeshwar Shrinath Baliga<sup>2</sup>

## Abstract

Giant cell tumor of the bone (GCTB) is a benign but locally aggressive tumor which has a predilection for the epiphyseo-metaphyseal region of long bones. However, the occurrence of GCT in surgically inaccessible locations such as the vertebrae and pelvis poses a daunting challenge. Receptor activator of nuclear factor kappa-B (RANK)-ligand binder, denosumab is a fully human monoclonal antibody which inhibits cells which expresses RANK ligand which is expressed in GCT. We report an unusual case report of recurrent GCT arising from the sacrum in a young man treated with denosumab. He underwent administration of denosumab pre-operatively and post-operatively whereby there was remission of the tumor. As a measure of "success," we indicate the social functioning-36 and WHO questionnaire which indicate a good quality of life.

**Keywords:** Giant cell tumor of the bone, denosumab, sacrum.

## Introduction

Giant cell tumor of the bone (GCTB) is a benign but locally aggressive tumor which has a predilection for the epiphyseo-metaphyseal region of long bones [1]. The presentation and symptoms are variable. It usually presents in patients between 30 and 50 years. Characteristically, it occurs as an osteolytic lesion and causes significant bone destruction. The overall incidence of the same is 1.3/million/year [2, 3]. Histologically, it is composed of sheets of neoplastic ovoid mononuclear cells with high receptor activator of nuclear factor kappa-B-ligand (RANKL) expression [4, 5, 6]. At times, malignant GCTB can occur. Pulmonary metastasis with an indolent presentation may occur in

2.1–6.6% of patients with advanced or recurrent GCTB [7,8].

Conventionally, GCTB is treated surgically, and the standard treatment strategies include extensive curettage with or without local adjuvants to en bloc resection. Recurrence of GCTB has been high as 65% for isolated curettage alone; 12–27% for curettage with local adjuvants (phenol, liquid nitrogen, and polymethylmethacrylate). Treatment of choice becomes a dilemma in such a scenario [9,10,11,12,13]. However, radiotherapy and bisphosphonate therapy have been traditionally reserved for recurrent and metastatic GCTB [1, 14]. RANK-ligand binder denosumab is a fully human monoclonal antibody which inhibits cells which express RANK

ligand–RANK interaction inhibits osteoclast formation and its activity [15]. This molecule, when administered subcutaneously, has been shown to suppress bone destruction in patients with osteolytic bone disease, multiple myeloma, or bone metastasis [4,5]. It has also been proven effective in bone disease affected in recurrent giant cell tumor [6]. GCT occurring in the spine and pelvis is often inaccessible surgically. In such scenario, denosumab will be of help and its efficacy has been proven before.

It is well known that bone pain and other skeletal-related events in bone tumors can undermine the quality of life (QOL) and compromise the patient's functional capabilities. In orthopedic oncology, the QOL is an important outcome to measure the success/failure of treatment. It is apt to include measures of the impact of disease and impairment on daily activities and behavior. The inability to participate in daily activities and hindrance to take care of his or her personal hygiene can lead to anxiety and depression. Hence, in this case, we

ligand. It binds to RANK ligand from activating its only receptor RANK on the surface of osteoclasts and their precursors. Prevention of

<sup>1</sup>Department of Ortho-Oncology, Mangalore Institute of Oncology, Mangalore, Karnataka India,

<sup>2</sup>Department of Radiation Oncology, Mangalore Institute of Oncology, Mangalore, Karnataka India,

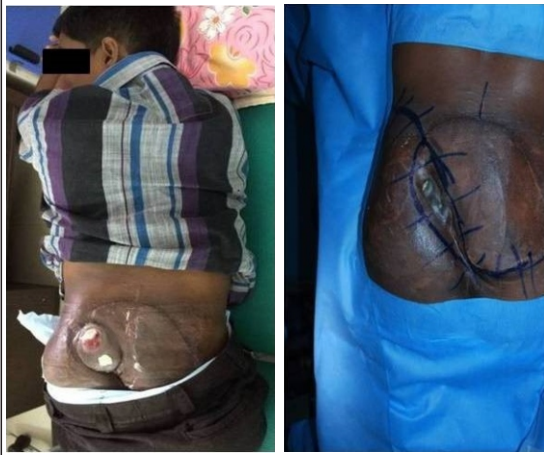<sup>3</sup>Department of Trauma and Orthopaedics, University Hospital of Wales, Cardiff, UK.

### Address of correspondence :

Dr. Suresh Rao,

Department of Radiation oncology, Mangalore institute of Oncology, Mangalore

E-mail: raos\_64@yahoo.com



**Figure 1:** Clinical image of the tumor during the first visit before initiation of treatment.

decided to measure his QOL by means of the WHO and social functioning (SF)-6 questionnaire [16,17,18]. At times, modern medicine is concerned only with the eradication of disease and symptoms. However, in a field such as orthopedic oncology, the need for the introduction of a humanistic element into health care is useful, and hence, we decided to incorporate the patient's current assessment of QOL.

The SF-36 is a Short Form Health Survey Questionnaire to evaluate the health-related QOL. It measures eight scales:

Physical functioning, role physical, bodily pain, general health (GH), vitality, SF, role emotional, and mental health. Two distinct outcomes – a physical dimension and a mental dimension – are measured [18]. The WHO-BREF questionnaire is a brief questionnaire on QOL. With the questions, it is possible to derive four domain scores which include physical health, psychological health, social relationships, and environment [17,18].

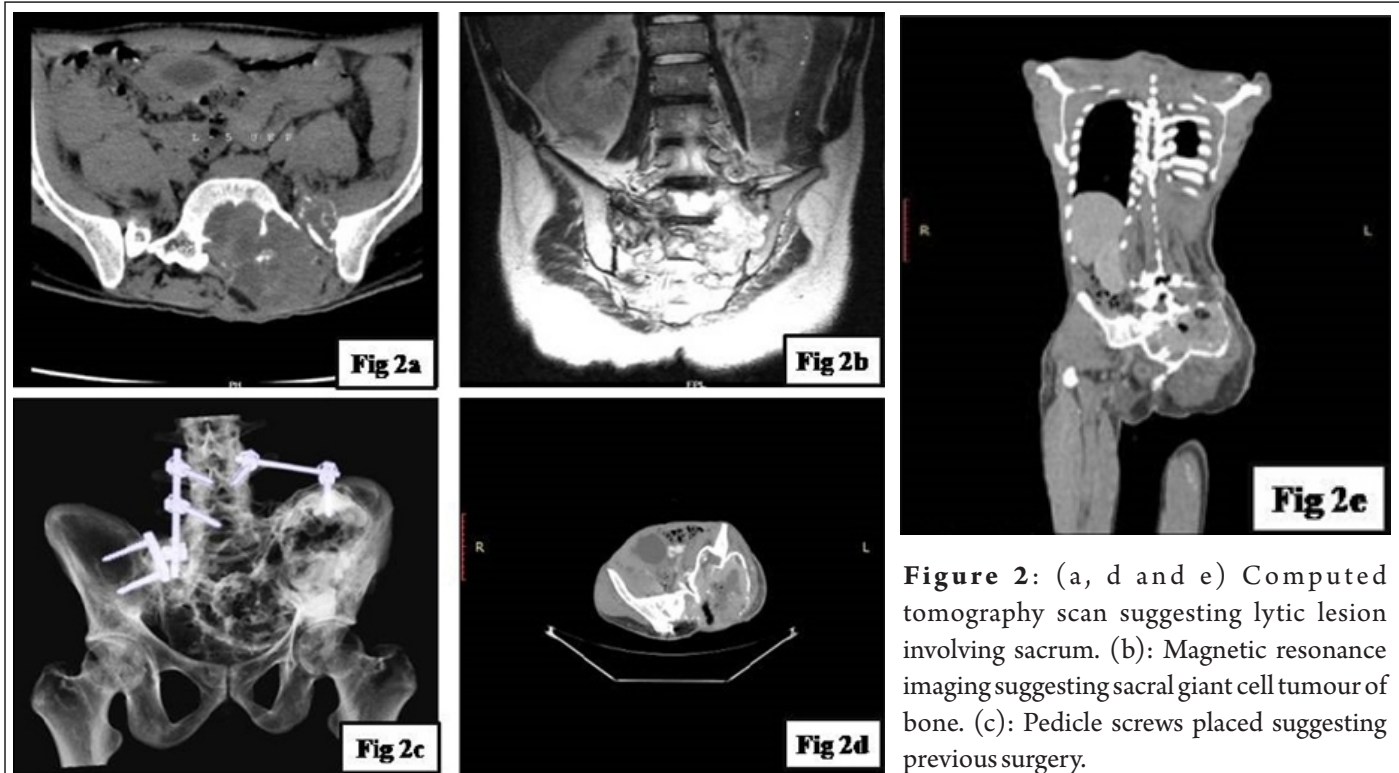
### Case Report

A 33-year-old male presented to us with severe back pain and left gluteal pain for the past 4 years with swelling in the lower back (Fig. 1). Clinical evaluation indicated that there were occasional radiculopathy, numbness in his left leg with weakness of dorsiflexion of ankle, and plantar flexion of toes. He had been diagnosed to have giant cell tumor of S1 vertebra (Fig. 2) and operated upon elsewhere with no relief of pain and persistence of swelling over the

lumbosacral spine. He also had persistent wound with sanguineous discharge from the previous surgery (Fig. 1). He used to have repeated blood transfusions on regular basis due to the same.

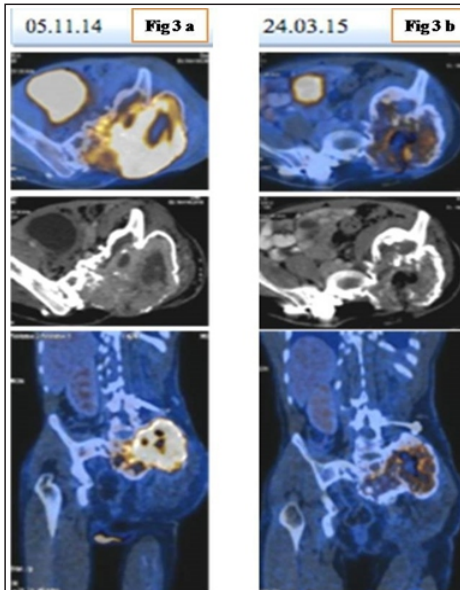
Radiographs at presentation suggested an osteolytic lesion engulfing the sacral vertebra and the left ilium (Fig. 2a). Computed tomography (CT) at the time of presentation to us was suggestive of a large expansile lytic lesion involving the left iliac bone and lower sacrum with internal hemorrhage (Fig. 2b). Pedicle screws on L4 and L5 pedicles on the right side and connecting rod from L4 to left iliac wing and into the sacroiliac joint were placed, suggesting previous surgery for removal of the tumor (Fig. 2c). Chest radiograph revealed no evidence of pulmonary metastasis. There was involvement of the multiple sacral neural foramina and left sacroiliac joint (Fig. 2d and e).

The positron emission tomography (PET)-CT performed confirmed a metabolically active osteolytic mass in the left half of the bony pelvis, sacrum, and L5 vertebra (Fig. 3a). Hence, it was diagnosed as a recurrent case of GCT



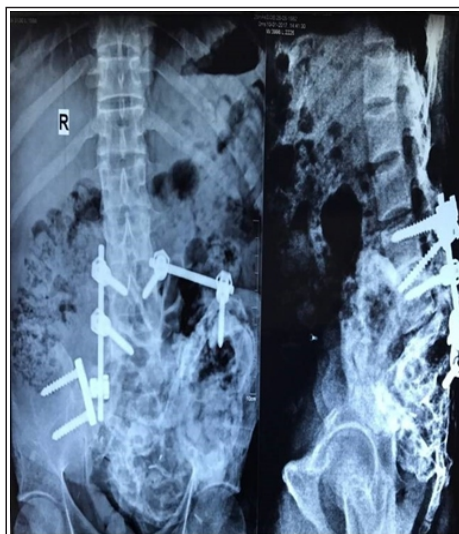**Figure 2:** (a, d and e) Computed tomography scan suggesting lytic lesion involving sacrum. (b): Magnetic resonance imaging suggesting sacral giant cell tumour of bone. (c): Pedicle screws placed suggesting previous surgery.





**Figure 3:** Positron emission tomography-computed tomography at the time of presentation (3 a) and after 4 months of treatment (3 b).

involving the sacrum and ileum and was decided to administer neoadjuvant denosumab. Loading of injection denosumab (120 mg) was given at 0, 8, and 15th day; it was later followed by 4 months of denosumab 120 mg being given subcutaneously. PET-CT was repeated at the end of 4 months (Fig. 3b) which suggested mild regression in the size of expansile osteolytic mass in the left hemipelvis, sacrum, and L5 vertebra. Subsequently, he underwent



**Figure 4:** Current X-ray suggesting new bone formation involving the sacrum and ilium.

embolization of the feeding vessels, followed by curettage of the recurrent tumor. He had an uneventful recovery post-operatively. There was no related systemic side effect which includes myalgia, diarrhea, rash, hypophosphatemia, or hypocalcemia. However, there was an episode of fever each lasting for an hour following the initial three injections of denosumab.

At subsequent follow-up, his pain reduced and resumed his day-to-day activities without much difficulty. He went back to his professional work in a span of 3 months after presenting to us. Post-operatively, in a span of 1 year, two doses of denosumab 120 mg have been administered in view of residual metabolic activity picked up in routine PET-CT. The current PET-CT scan shows regression of nodular metabolically active soft-tissue lesions, predominantly in the left iliac crest lesion and in the left proximal sacral lesions (Fig. 4). The current X-ray shows sclerosis of the sacrum and left iliac bone which suggests new bone formation (Fig. 5). Pain and radiculopathy had reduced drastically with no hampering of his day-to-day activities.

Hematological reports at his latest follow-up suggested the erythrocyte sedimentation rate and C-reactive protein to be normal. Hepatic enzymes (aspartate aminotransferase and alanine aminotransferase) were normal. Cardiac enzyme (creatinine kinase) and electrocardiogram were within the normal limits. Biochemical parameters of calcium, phosphorous, and Vitamin D were normal. The latest follow-up (3-year post-surgery and following denosumab injections) showed sclerosis at the area of involvement. This would suggest improvement or amelioration of the symptoms. The patient, however, receives denosumab injections once every 6 months.

In this patient, the SF-36 questionnaire produced the following score scales: Physical function – 95, role limitations

due to physical health – 75, role limitations due to emotional problems – 100, energy/fatigue – 90, emotional well-being – 96, SF – 100, pain – 100, and GH – 65, and the WHO-BREF produced a score of Domain 1 score – 26, Domain 2 score – 23, Domain 3 – 14, and Domain 4 – 39. With this score, it can be inferred that the patient is satisfied with the treatment and bears a good QOL.

### Discussion

GCTB is one of the most common benign tumors accounting for 5% of all tumors [1]. There has been an array for treatment modalities for recurrent GCTB. More aggressive treatment options including resection of the tumor may lead to the future reconstructive dilemma and thus are generally avoided. In such scenarios, radiotherapy with 35–40 Gy has demonstrated promising results [15]. However, the risk of malignant transformation of GCT and the morbidity associated with it, limited its use. In this setup, the role of denosumab is redefined. Denosumab thus may be helpful in controlling the aggressive osteolytic nature of the giant cell tumor.

Denosumab is a highly effective monoclonal antibody against the RANK ligand expressed by the neoplastic stromal cells in GCT, and the use of this molecule in GCTB has been extensively studied [3, 4, 14, 15, ]. It can be administered in both salvageable and unsalvageable tumors with equally good results. In our case, since the lesion was extensive and involved the sacrum, we decided to administer denosumab pre-operatively in the prospect of reducing the tumor load. Similar regimen has been described in the literature before [19, 20]. Heijden et al. described its use in giant cell tumor involving the ischium and demonstrated the decrease in the size of the tumor after denosumab administration [19]. Similarly, in our patient, the PET-CT done at the time of evaluation and at the end of 4 months of serial monthly, denosumab injections

showed decreasing trend in tumor metabolic activity (Fig. 4).

Inaccessible and inoperable GCTB as in sacral and spinal GCTB have shown good response to the use of denosumab. Vaishya et al described denosumab administration in a recurrent GCT with intractable pain affecting the sacrum and was treated successfully [21]. There are several studies which support the use of denosumab in recurrent GCTB. Borkowska et al. concluded that there is high tumor response to denosumab and can be put forward as a standard regimen drug for the treatment of recurrent GCT. However, its pre-operative duration of administration is debatable and concluded a shorter time period of administration of denosumab for GCT when only an intralesional curettage was planned and longer duration (4–6 months) where tumor resection was planned [22]. In our case, we had started denosumab pre-operatively for 4 months followed by curettage. However, there are no consensus reached in the duration of denosumab to be administered pre-operatively [3,15]. Recurrence following administration of denosumab is also reported and remains a dilemma. The duration of treatment in case of unresectable tumors is questionable and remains unanswered.

Literature is divided into the role of continuation of denosumab in recurrence of GCTB [2,3]. In our case, we had administered denosumab 6 monthly apart, as the routine PET-CT had picked up metabolic activity at the tumor location. We feel that administration of denosumab may be continued in cases where the tumor has not been completely removed or is inoperable. This opinion has also been supported by Gaston et al. in his case report [2]. The time interval between the administrations remains inconclusive, and we feel that it should be decided on a case-to-case basis depending on the PET-CT activity in follow-up scans. Large cohorts of patients in the group of “inoperable GCTB” are required to prove the hypothesis of continuation of denosumab in such cases. Palmerini et al. demonstrated sustained clinical benefit in a cohort of patients, including pain relief and radiological disease control. They demonstrated these effects in patients with a follow-up of up to 6 years. In their study, patients on prolonged denosumab treatment experienced mild peripheral neuropathy, skin rash, and hypophosphatemia. However, there were no consensus drawn on the duration of denosumab to be administered [23].

Toxicity is another aspect of prolonged denosumab administration [4,5,15]. Long-term toxicity including cardiotoxicity and hepatotoxicity has been reported in literature. Most common adverse effects reported are fatigue and nausea. Hypocalcemia is a known toxicity. However, in our case, we did not observe these in the patient.

### Conclusion

Denosumab may be included in the multidisciplinary treatment management of recurrent GCTB with good tumor response rates. However, large multicentric trials have to be undertaken to know its efficacy, tolerability, and the duration of treatment. We feel that continuation of denosumab in recurrent and unresectable GCTB is debatable and has to follow-up in a large cohort of patients.

### References

- Balke M, Schremper L, Gebert C, Ahrens H, Streitbuenger A, Koehler G, et al. Giant cell tumor of bone: Treatment and outcome of 214 cases. *J Cancer Res Clin Oncol* 2008;134:969-78.
- Gaston CL, Puls F, Grimer RJ. The dilemma of denosumab: Salvage of a femoral head giant cell tumour. *Int J Surg Case Rep* 2014;5:783-6.
- Gaston CL, Grimer RJ, Parry M, Stacchiotti S, Dei Tos AP, Gelderblom H, et al. Current status and unanswered questions on the use of denosumab in giant cell tumor of bone. *Clin Sarcoma Res* 2016;6:15.
- Liede A, Bach BA, Stryker S, Hernandez RK, Sobocki P, Bennett B, et al. Regional variation and challenges in estimating the incidence of giant cell tumor of bone. *J Bone Joint Surg Am* 2014;96:1999-2007.
- Xu SF, Adams B, Yu XC, Xu M. Denosumab and giant cell tumour of bone-a review and future management considerations. *Curr Oncol* 2013;20:e442-7.
- Dufresne A, Derbel O, Cassier P, Vaz G, Decouvelaere AV, Blay JY, et al. Giant-cell tumor of bone, anti-RANKL therapy. *Bonekey Rep* 2012;1:149.
- Chan CM, Adler Z, Reith JD, Gibbs CP Jr. Risk factors for pulmonary metastases from giant cell tumor of bone. *J Bone Joint Surg Am* 2015;97:420-
- Dominkus M, Ruggieri P, Bertoni F, Briccoli A, Picci P, Rocca M, et al. Histologically verified lung metastases in benign giant cell tumours--14 cases from a single institution. *Int Orthop* 2006;30:499-504.
- Balke M, Schremper L, Gebert C, Ahrens H, Streitbuenger A, Koehler G, et al. Giant cell tumor of bone: Treatment and outcome of 214 cases. *J Cancer Res Clin Oncol* 2008;134:969-78.
- Becker WT, Dohle J, Bernd L, Braun A, Cserhati M, Enderle A, et al. Local recurrence of giant cell tumor of bone after intralesional treatment with and without adjuvant therapy. *J Bone Jt Surg Am* 2008;90(5):1060e7.
- Kivioja AH, Blomqvist C, Hietaniemi K, Trovik C, Walloe A, Bauer HC, et al. Cement is recommended in intralesional surgery of giant cell tumors: A Scandinavian sarcoma group study of 294 patients followed for a median time of 5 years. *Acta Orthop*

- 2008;79:86-93.
12. Algawahmed H, Turcotte R, Farrokhyar F, Ghert M. High-speed burring with and without the use of surgical adjuvants in the intralesional management of giant cell tumor of bone: A systematic review and meta-analysis. *Sarcoma* 2010;2010:1-5.
  13. Errani C, Ruggieri P, Asenzio MA, Toscano A, Colangeli S, Rimondi E, et al. Giant cell tumor of the extremity: A review of 349 cases from a single institution. *Cancer Treat Rev* 2010;36:1-7.
  14. Coleman RE, McCloskey EV. Bisphosphonates in oncology. *Bone* 2011;49:71-6.
  15. Thomas D, Henshaw R, Skubitz K, Chawla S, Staddon A, Blay JY, et al. Denosumab in patients with giant-cell tumour of bone: An open-label, phase 2 study. *Lancet Oncol* 2010;11:275-80
  - 16 . World Health Organization. Quality of Life Group: WHOQOLsBREF Introduction. Administration and Scoring Field Trial  
Version. Geneva: World Health Organization; 1996
  - 17 . The world health organization quality of life assessment (WHOQOL): Development and general psychometric properties. *Soc Sci Med* 1998;46:1569
  - 18 Ware JE Jr., Sherbourne CD. The MOS 36-item short-form health survey (SF-36). I. Conceptual framework and item selection. *Med Care* 1992;30:473-83.
  19. Heijden LV, Sande MA, Hogendoorn PC, Gelderblom H, Dijkstra PS. Neoadjuvant denosumab for extensive giant cell tumor in os ischium—a case report. *Acta orthopaedica*. 2015 ;86:393-5.
  20. Rutkowski P, Ferrari S, Grimer RJ, Stalley PD, Dijkstra SP, Pienkowski A et al. Surgical downstaging in an open-label phase II trial of denosumab in patients with giant cell tumor of bone. *Ann Surg Oncol* 2015;22:2860-8.
  21. Vaishya R, Agarwal AK, Vijay V. 'Salvage treatment' of aggressive giant cell tumor of bones with denosumab. *Cureus*. 2015 Jul;7(7).
  22. Borkowska A, Goryń T, Pieńkowski A, Wągradzki M, Jagiełło-Wieczorek E, Rogala P, et al. Denosumab treatment of inoperable or locally advanced giant cell tumor of bone. *Oncol Lett* 2016;12:4312-8
  23. Palmerini E, Chawla NS, Ferrari S, Sudan M, Picci P, Marchesi E, et al. Denosumab in advanced/unresectable giant-cell tumour of bone (GCTB): For how long? *Eur J Cancer* 2017;76:118-24.

**Conflict of Interest: NIL**  
**Source of Support: NIL**

#### How to Cite this Article

Chinder P, Rao S, Mathai NJ, Shrinath Baliga M S. Recurrent Giant Cell Tumor of Sacrum Treated with Denosumab: A Case Report. *Journal of Karnataka Orthopaedic Association*. May-Aug 2019; 7(2): 38-42.