



Indian J Plast Surg. 2012 Sep-Dec; 45(3): 581–583.
doi: 10.4103/0970-0358.105988: 10.4103/0970-0358.105988

PMCID: PMC3580371
PMID: [23450932](#)

Snapping wrist due to lunate malformation

[Pramod S. Chinder](#), [B. Jagannath Kamath](#),¹ [Deepak Hegde](#),² and [Mayur Rai](#)¹

Department of Musculoskeletal Oncology, HCG Bangalore Institute of Oncology, Bangalore, India

¹Department of Orthopaedics, KMC, Mangalore, India

²Department of Orthopaedics, KS Hegde Medical College, Mangalore, India

Address for correspondence: Dr. Pramod S. Chinder, Department of Musculoskeletal Oncology, #8, HCG-Bangalore Institute of Oncology, P Kalinga Rao Road, Sampangiram Nagar, Bangalore - 560 027, Karnataka, India. E-mail: drpramods@gmail.com

Copyright : © Indian Journal of Plastic Surgery

This is an open-access article distributed under the terms of the Creative Commons Attribution-Noncommercial-Share Alike 3.0 Unported, which permits unrestricted use, distribution, and reproduction in any medium, provided the original work is properly cited.

Sir,

The bony block causing snapping of the wrist is an infrequently encountered phenomenon. We came across such a situation in our clinic, which has been described. In our rare clinical situation, we encountered a phenomenon of lunate remodelling where the lunate, due to a constant wrist flexion and loose dorsal capsule (secondary to burn contracture) got remodelled and was blocking the wrist extension. Bony deformities are liable to occur due to imbalance of muscle power and poor posture. There is also disuse atrophy of muscles, which may eventually lead to bone remodelling. This phenomenon has been well explained in postpolio deformities.[1] As the pathology in this case is fibrosis, adhesions and contracture, capsulectomy and removal of bony block was considered appropriate as mentioned by Curtis RM in the management of neglected postburn stiff hands.[2,3] Curtis has explained the need of the capsulectomy in managing the proximal interphalangeal joint (PIP) contractures after analysing 50 patients with various injuries to the PIPs.[2] The snapping of the wrist has been previously described by Jackson *et al.*[4] due to scapholunate subluxation. In the same article, they have mentioned few cases causing snapping due to scapholunate subluxation and they have stressed on the need of fluoroscopy in such cases. The snapping was mainly on the radial and ulnar deviations of the wrist, and was associated with pain. None of the reports or studies has reported bony remodelling as the cause for snapping. This report describes a rare and interesting incidence in a postburn contracture of the wrist and the management by eliminating the block and capsulectomy.

A 26-year-old teacher presented to us with a postburn contracture of her left wrist. She complained about her inability to extend her wrist without assistance while dusting the blackboard; she had to support her wrist with her right hand. After examination, it was determined that she had a dropped wrist that was only able to extend from 50° flexion to 30° flexion [Figure [1a](#) and [b](#)]. Following assistance, she was able to extend from 30° flexion to 10° extension [Figure [1c](#)] [[Video 1](#)]. There was a fixed flexion deformity of PIPJ and Distal interphalangeal joint of Little Finger due to the burn contracture. The rest of her joints are in a fairly good functional position. Because of the constantly flexed position of the wrist, all the metacarpophalangeal joints have hyperextended to compensate for the wrist's flexion during her activities of daily living.

[Click here to view as Video 1](#)

After radiographic examination using X-rays and computed tomography scans, we found that the lunate bone was deformed on the dorsum and on fluoroscopy [Figure [2a](#), and [b](#)]. Using an image intensifier [[Video 2](#)], the deformed part was found to be blocking the wrist extension along with mild subluxation of lunate dorsally, which caused it to snap once a brief dorsal pressure was given. Hence, we assumed that once this problem of malformation seen in computed tomography [[Video 3](#)] and subluxation is addressed, she should have better hand function and be able to grasp her duster while teaching.

[Click here to view as Video 2](#)

[Click here to view as Video 3](#)

Under Bier block, with the help of image intensifier, through the lazy S incision centering over lunate, we shaved the dorsal deformed blocking part, which included a part of intraarticular lunate on the proximal radial side and double-breasted the attenuated dorsal capsule. Intraoperatively, we confirmed that there was no residual block by asking her to extend her wrist. The little finger contractures were released to a more functional position with "Z" plasties. A postoperative wrist splint was placed in a neutral position for 3 weeks. After the third week, the range of motion was increased to the present status.

Presently, she has an active flexion from 0° to 80° and active extension of 0° to 10° without any problems. Her functional ability to grasp objects has been significantly improved with nearly 75% of the opposite 2 years after the procedure [[Video 4a](#) and [b](#)].

[Click here to view as Video 4](#)

[Click here to view as Video 5](#)

The snapping of the wrist due to scapholunate subluxation has been described earlier due to various conditions. The lunate deformity causing snapping or triggering has not been described before. Also, the phenomena of accommodation due to a constant flexed position of the wrist, all the

while with her metacarpophalangeal joints being hyperextended, facilitated some amount of grasping. This has, in fact, helped her gain an extra range of motion compensating for the loss of flexion in all the joints of fingers. Any attempt at correcting metacarpophalangeal joint hyperextension will worsen her hand function rather than improving it. She did not have any extrinsic flexion contractures due to the constant flexed position of her wrist. Hence, by eliminating the bony block and correcting little finger contractures, we achieved a well-functioning hand.

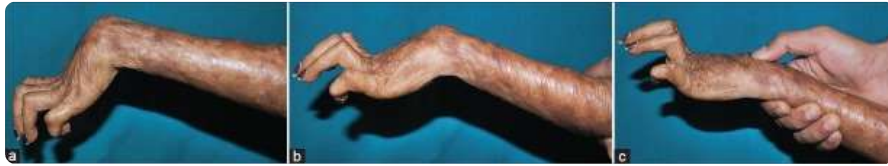See Video on: www.ijps.org

REFERENCES

1. Frustace SJ. Poliomyelitis: Late and unusual sequelae. *Am J Phys Med.* 1987;66:328–37. [PubMed: 3324771]
2. Curtis RM. Capsulectomy of the interphalangeal joints of the fingers. *J Bone Joint Surg Am.* 1954;36-A:1219–32. [PubMed: 13211714]
3. Curtis RM. Stiff finger joints. In: Grabb WC, Smith JW, editors. *“Plastic Surgery”*. 3rd ed. Boston: Little Brown; 1979. pp. 598–603.
4. Jackson WT, Protas JM. Snapping scapholunate subluxation. *J Hand Surg Am.* 1981;6:590–4. [PubMed: 7310085]

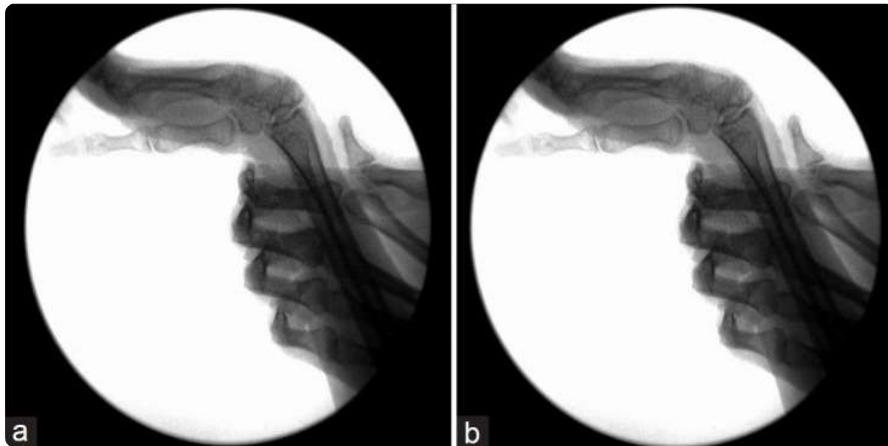
Figures and Tables

Figure 1



(a) Resting flexed posture of the hand. (b) Active extension gets stopped at this level. (c) Upon dorsal pressure over the lunate, the extension continues to 10° extension improving the hand opening

Figure 2



(a) Fluoroscopic image of the wrist in normal resting position. (b) Fluoroscopic image of the wrist upon dorsal pressure